

In the name of God



Shiraz E-Medical Journal
Vol. 9, No. 4, October 2008

<http://semj.sums.ac.ir/vol9/Oct2008/87003.htm>

Comparison of Characteristics of Caudal Block in Two Different Approaches: Trans-Sacral and Trans-Sacral Hiatus.

Shahriari A *, Heidari MH **, Roudbari M ***.

*Instructor, Assistant Professor, Department of anesthesiology, School of Medicine, Zahedan University of Medical Sciences, Zahedan, Iran. ** Assistant Professor, Section of Anatomy, Department of Medicine, Shahid Beheshti University of Medical Sciences, Tehran, Iran. *** Associate Professor of biostatistics, Dept. of Mathematics and Statistics, Iran University of Medical Sciences, Tehran, Iran.

Correspondence: Dr. A. Shahriari, Dept. of Anesthesiology, School of Medicine, Zahedan University of Medical Sciences, Khatam al Anbia Hospital, Postal code 98157 Zahedan, Iran, Telephone: +98 (915) 141-9158, Email: alibenmahdi@yahoo.com

Received for Publication: March 1, 2008, Accepted for Publication: September 25, 2008.

Abstract:

Background: Caudal block offers a good and safe postoperative analgesia in pediatric patients. In a randomized study we have examined the characteristics and mean duration of analgesia after caudal anesthesia performed with two different routes: trans-sacral and trans-sacral hiatus.

Methods: Forty boys in Ali-Ebne-Abitaleb Hospital of Zahedan undergoing hypospadias repair were randomly allocated in two groups to receive bupivacaine 1.5mg/kg from sacral route in one group and from sacral hiatus route in the control group. Postoperative pain and sedation scores were assessed for 12 hr after operation.

Results: The time of first requiring of additional analgesia did not differ significantly between two groups (365±40 min in sacral group vs 390±35 min in trans-sacral-hiatus group) (P value=0.17). Side effects were not seen in any patients. Two groups were comparable with regards pain scores and sedation scores at 1 and 7h (P > 0.05).

Conclusions: We concluded that the trans-sacral route is an acceptable, safe and easy method for performing caudal block, but total duration of analgesia did not differ with these two methods.

Keywords: Caudal anesthesia, Sacral Hiatus, Trans-sacral.

Introduction:

Caudal block is the regional technique that is used with the greatest frequency in pediatric patients. Its use was first described in 1933, ⁽¹⁾ but it gained great popularity only in the early 1960.⁽²⁾ Caudal block is commonly practiced by 96% of pediatric anesthesiologists of UK.⁽³⁾ Although such a diffusion, several limitations of this technique must be considered: at first it is a single shot technique, due to high risk of catheter contamination from fecal soiling.⁽⁴⁾ Furthermore high cephalic spread can be obtained only by injection of large volume of anesthetics solutions. Finally, several complications of this block were reported.⁽⁵⁾ Caudal block have been seen to be effective in regard to suppressing the stress response as reflected in epinephrine and norepinephrine blood levels in orchidopexy patients.⁽⁶⁾

The aim of this study is to compare the anesthetic characteristic of caudal block with two different routes of drug administration (trans-sacral and trans-sacral hiatus). Caudal block by trans-sacral hiatus approach is a routine technique used by anesthesiologists, but the other technique is not routine. Comparing the complications between these two different techniques of caudal block needs to a very large sample size, so the results of this clinical trial study can be useful for the anesthesiologists to choose one of these techniques for their routine practice according to the simplicity, advantage and disadvantage of each technique.

Methods and Techniques:

The sacral hiatus marks the termination of the sacral canal and results from failure of fusion of the fifth and usually fourth vertebral arches.

The sacrum and sacral hiatus are extreme variable anatomical structures. However, the equilateral triangle located between the apex of the sacral hiatus and superolateral sacral cornua will certainly be useful in determining the location of sacral hiatus during the block.⁽⁷⁾ To perform a block, the sacral hiatus must first be located and a needle passed through the sacrococcygeal membrane. Ivani proposed a variation of the original technique, entering the needle at 60° angle and injecting the drug directly after the perforation of sacrococcygeal ligament, reducing the risk of dural puncture, vascular damage or intraosseous injection.⁽⁸⁾

As was Described by P. Busoni (one of the fathers of pediatric locoregional anesthesia) ^(9, 10), the trans-sacral route is an acceptable method for caudal epidural injection in pediatric anesthesia.⁽¹¹⁾ Sacral epidural block (S2-S3 intervertebral space, P. Busoni's method) is as safe and easy as caudal block ⁽¹²⁾ and it seems that in this method, there is a lower risk of contamination from fecal soiling.

The present prospectively designed study was approved by the ethics and clinical studies committee of Zahedan University of Medical Sciences and informed and signed consent was obtained from the parents of all the patients who were enrolled in the study.

We enrolled forty healthy boys aged 4-8 years, classified as ASA I scheduled for hypospadias repair in Ali-Ebne-Abitaleb Hospital of Zahedan, Iran in 2005. Patients who had contraindications to caudal anesthesia or have an anomaly in sacral anatomy were excluded. Participants were allocated randomly by a computer generated randomization scheme randomly to one of two groups (n = 20), trans-sacral or control groups. One anesthesiologist was responsible for performing caudal block, and another anesthesiologist that managed the patients in the time of surgery and in the recovery room was not aware of group assignment. All patients were fasted 6 hours before surgery.

No premedication was used. Pulse oxymetry, non invasive blood pressure and EKG monitoring were used for all patients. After cannulation of a vein, anesthesia was induced with atropine 0.01mg/kg, thiopentone 5mg/kg, fentanyl 2 μ g/kg. In all patients anesthesia was maintained with inhalation of mixture of O₂ 50%, N₂O 50% and sevoflurane 8% delivered by a Mapelson D system by a face mask. After tracheal intubation and when an adequate level of anesthesia was attempt, after lateral positioning of patients and after preparation of the place with povidone-iodine, using a 22G needle, bupivacaine 1.5mg/kg (diluted with 0.9% saline if required for reaching a volume of 0.8 ml/kg) was injected to caudal extradural space. The solution was injected by a trans-sacral approach in group S, and by inserting the needle from sacral hiatus in control group (group C). The angel of

needle entrance for trans-sacral approach was 45-60° angle using S2-S3 space.

All patients received 5ml/kg Dextrose 5% in 0.45 saline in the time of surgery. Surgery was allowed to begin 10 min after performing the block. Sevoflurane was maintained at 4% concentration after caudal epidural injection and then reduced 1% every 10 minutes for reaching at a concentration of 2% until the end of surgery and fentanyl was repeated 1 μ g/kg after 20 minutes. Failed block defined when it was necessary to add intra operative fentanyl, or to increase the concentration of the inhaled anesthetics, in response to a 20% increase for more than 5 min of the systolic blood pressure and/or heart rate from the baseline values.

All patients were observed for 2 hours in the recovery room. When the child was awake in the recovery room, objective pain assessments, respiratory rate, blood pressure and heart rate were recorded by a nurse investigator unaware of patients grouping. Assessment were made at 15 min intervals for the first hour, 30 min intervals for the second hour, and intervals of 1 hours until 12 h after caudal injection. The observer scored pain on each visit with reference to six-points scale: 1-2: none-insignificant pain; 3-4: moderate pain; 5-6: severe pain, total analgesia duration and mean hourly pain scores were recorded.

Acetaminophen suppository was administered for pain score \geq 3 and the time of first analgesic requirement was recorded.

Motor block was assessed after awaking of the patients using a modified Bromage scale (0: no paralysis; 1: unable to raise extended leg; 2: unable to flex knee; 3: unable to flex ankle).

Sedation was scored with reference between 1 (calm), 2 (easily calmed), 3 (calm-moderately agitated), and 4 (combative), in the recovery room and was recorded.

Statistical test were performed using SPSS 11 for Windows. Results are reported as absolute value, mean \pm SD. Continuous variables were analyzed using Student's T test. Nominal or ordinal variables were analyzed by Chi square test and Fisher exact test or Mann-Whitney U test. $P < 0.05$ was considered statistically significant.

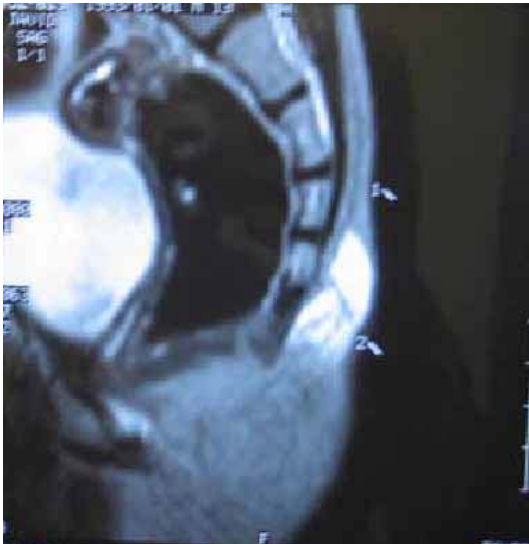

Figure 1 represents a sagittal MRI image of the sacral bone of a 6 years boy after insertion of two plastic cannula showing the direction of the sacral hiatus and showing the direction of trans-sacral route. After preparation and local anesthetic

infiltration of the region (the infiltration site can be seen in the image, white area). The inter-sacrum route was marked: 1, The trans-sacral hiatus membrane route was marked: 2.

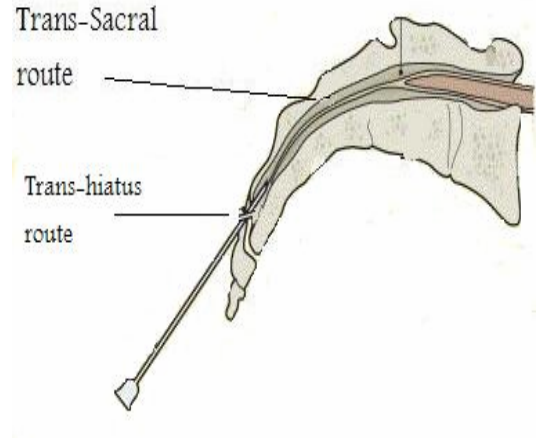


Figure 2, Schematic drawing of the needle insertion.

Results:

Demographic data regarding to median weight and duration of the surgery of the patients were similar in two groups (Table1).

Table 1: Patients demographic data in two groups: Patient in trans-sacral group or trans-sacral hiatus group (Control group).

Variables	trans-sacral group mean \pm SD	Control group mean \pm SD
Age (year)	5.3 \pm 1.2	5.0 \pm 0.86
Weight (kg)	15.6 \pm 3.6	15.57 \pm 4.1
Surgery duration (min)	45.5 \pm 11.6	50 \pm 13.45

Two patients were removed from the control group because of unsuccessful caudal injection and their trial numbers were reassigned to subsequent patients, so the success rate can be calculated in two groups: 20/20 = 100% in the trans-sacral

group, and 20/22= 90% in the trans-hiatal approach group.

additional analgesia did not differ significantly between two groups (365±40 min versus 390±35 min; P =0.17)

Pain scores measured in two groups at 1 h and 6h and 7h after operation were similar (Table 2).

No patient in the recovery room required analgesia. The time of first requiring of

There were no significantly differences between two groups in sedation scores measured at 1 h and 7 h after operation (Table2).

Table 2- Pain scores at 1h and 6h and 7h and Sedation score at 1h and 7h in two groups: trans-sacral group (Group S) or trans-sacral hiatus group (Control group).

Pain or sedation score	trans-sacral group Median Range		Control group Median Range		P value*
Pain Score at 1h	1.35	1-2	1.5	1-2	0.33
Pain Score at 6h	2.25	2-3	2.25	2-3	1
Pain Score at 7h	2.8	2-3	2.9	2-3	0.74
Sedation score at 1h	2.2	2-3	2.3	2-3	0.35
Sedation score at 7h	2.8	2-3	2.9	2-3	0.82

*P<0.05 statistically significant.

All patients have a motor score block of 1 examined 30 min after arrival in the recovery room. Nausea and vomiting were not seen in any patients.

Discussion:

We have not expected a significant difference in analgesic duration and pain scores between these two groups when we designed this study. The point of injection in two approaches only differs by approximately 2-3 cm.

Analgesic duration in our study was 330 to 390 minutes. Assessment of pain relief has proved to be difficult in young children, so we can see a different results in analgesic duration between studies, for example Hannallah et al ⁽¹³⁾ reported a mean analgesic duration of 219 min (3.6h), but Shobha Malvia et al reported an analgesic

effect of at least 12h after caudal block.⁽¹⁴⁾ Analgesic requirements may vary 5-7- fold in the postoperative period for the same surgical procedure.⁽¹⁵⁾

The survey by Giaufre reported for caudal block, a rate of complication of 0.7/1000. Complication included: dural puncture, intravascular injection, difficult injection of anesthetic solution, rectal penetration, drug overdose, morphine apnea and skin lesion.⁽⁴⁾ One of the limitations of our study was the small number of participants which do not allow us to compare the rate of complications or success rate of caudal block with these two methods between the groups.

Prosser et al using bupivacaine for caudal anesthesia in their study have found an incidence of 10.7% emesis,32.1% flushing

and 3.6% pruritus in their patients ⁽¹⁶⁾, but we have not found such frequency, perhaps because the participants children in their study is very younger than our study.

Crighton et al found in their study using magnetic resonance imaging, the inferior extremity of the dura in adults at the middle third of S2, with some variations ⁽¹⁷⁾, but the termination of dural sac can be lower in children and most care is required to avoid dural puncture in small children in trans-sacral approach.

In a study performed at Johns Hopkins Hospital, 21 of 170 caudally inserted epidural catheters developed cellulitis. Catheter tip colonization with gram-negative organisms was significantly higher in the caudal as compared with the lumbar group. Both caudal and lumbar catheters had an approximate 25% gram-positive colonization incidence. However, only 1 out of 40 lumbar insertion sites developed cellulitis. There were no cases of an epidural abscess.⁽¹⁸⁾ Cellulitis was not reported as a complication of a single shot caudal block, but it seems that in the trans-sacral approach, there is a lower risk of contamination from fecal soiling.

Kil et al found in their study a success rate of 100% among 76 children undergoing caudal block with a trans-hiatal approach compared with a 96.3% success rate among 81 patients undergoing caudal block with a trans-sacral approach.⁽¹⁹⁾ The mean duration of analgesia in two groups was not reported in their study.

Conclusion:

It seems that sacral approach could be an acceptable, safe and easy method for performing caudal block and we have not seen any complication using this method.

The trans-sacral route can be an alternative method for caudal block with a theoretical lower risk of infection. However, care is required to avoid dural puncture in small infants because the dural sac is commonly terminated at the S2 level.

Acknowledgment:

We thank Radiology Department, University Hospital, Ali Ebne Abitaleb for their assistance.

References:

1. Campbell MF. Caudal anesthesia in children. *Am J Urol* 1933; 30: 245-9.
2. Polaner DM, Suresh S and Cote CJ. Pediatric regional anesthesia. In: Cote CJ, Ryan JF, editors. *A practice of anesthesia for infants and children*. 3rd Edition. Philadelphia: W.B. Saunders company; 2001.p467.
3. Saunders JC. Pediatric regional anesthesia, a survey of practice in United Kingdom. *Br J Anesth* 2002; 89: 707-10.
4. Silvani P, Camporesi A, Agostinu M R, Salvo I. Caudal anesthesia in pediatrics: an update. *Minerva Anesthesiol* 2006; 72: 453-9.
5. Giafre E, Dalens B, Goumbert A. Epidemiology and morbidity of regional anesthesia in children: A one year prospective survey of the French-Language society of pediatric anesthesiologists. *Anesth Analg* 1996; 83: 904-12.
6. Sonri M, Gaitini LA, Vaida SJ, Yanovski B, Sabo E, Levy N et al. Effects of ilioinguinal nerveblock on the catecholamine plasma levels in orchidopexy: comparison with caudal epidural block. *Pediatr Anesth* 2002; 12: 791-7.
7. Senoglu N, Senoglu M, Oksus H, Gumusalan Y, Yuksel KZ, Zencirci B et al. Landmarks of the sacral hiatus for caudal epidural block: an anatomical study. *Br J Anesth* 2005; 95: 692-5.

8. Ivani G, caudal block: 'no turn technique'. *Pediatr Anesth* 2005; 15: 80-4.
9. Busoni P, Sarti A. Sacral intervertebral epidural block *Anesthesiology*. 1987; 67: 993-995.
10. Busoni P. Trans-sacral extradural anesthesia in pediatrics. *Cah Anesthesiol*. 1992; 40: 484-486.
11. Saint-maurice C, Laundais A, Othmani H, Khalloufi M. The trans-sacral route. Can be the technique be simplified? *Cah Anesthesiol*. 1993; 41(3): 235-6.
12. Quinot JF, Coquelin G. Trans-sacral caudal anesthesia in ambulatory practice in infants. Our experience. *Cah Anesthesiol*. 1993; 41(4): 347-8.
13. Hannallah RS, Broadman LM, Belman AB, Abramowitz M D, Epstein BS. Comparison of caudal blocks and ilioinguinal/iliohypogastric nerve blocks for control of pain in pediatric ambulatory surgery. *Anesthesiology* 1997; 66: 832-4.
14. Shobha M, David W, Fear W, Larence R, Jerrold L, Adequacy of caudal analgesia in children after penoscotal and inguinal surgery using 0.5 or 1 ml/kg bupivacaine 0.125%. *Can J anesth* 1992; 39: 5: 449-53.
15. Morton NS. Development of monitoring protocol for safe use of opioids in children. *Pediatr Anesth* .1993; 3: 179-184.
16. Prosser D P, Davis A, Booker P D and Murray A. Caudal tramadol for postoperative analgesia in paediatric hypospadias surgery. *Br J Anesth* 1997; 79: 293-296.
17. Crighton IM, Barry P B, Hobbs G J. a study of the anatomy of caudal space using magnetic resonance imaging. *BR J Anesth* 1997; 78: 391-5.
18. Kost-Byerly S, Tobin JR, Greenberg RS, Bacterial colonization and infection rate of continuous epidural catheters in children. *Anesth Analg* 86 (1998), pp. 712-716.
19. Kil H, Shin S, Song Y, Oh S, Hong J. An Alternative Approach to Caudal Block in Children: Comparison of the Sacral Intervertebral Approach and Sacral Hiatal Approach. *Reg Anesth Pain Med*, 2008, (33) 5, Suppl 1: 5