

Shiraz E-Medical Journal
Vol. 12, No. 4, October 2011

<http://semj.sums.ac.ir/vol12/apr2011/90002.htm>

Testing Global Histogram Equalization and Unsharp Mask Algorithms for Processing Conventional Chest X-Ray Images.

Mohammadi A*, Aghazadeh J**, Ghate AA*, Moosavi-toomatari SB***, Sepehrvand N±, Moosavi-toomatari SE≠, Mohammad Ghasemi-rad M***.

* Associate Professor, Department of Radiology, ** Assistant Professor, Department of Neurosurgery, Imam Khomeini Training Hospital, Urmia University of Medical Sciences, Urmia, Iran, *** Medical Doctor, Students' Research Committee, Urmia University of Medical Sciences, Urmia, Iran, ± Medical Doctor, National Institute of Health Research, Tehran University of Medical Sciences, Tehran, Iran, ≠ Medical Intern, Students' Research Committee, Tabriz University of Medical Sciences, Tabriz, Iran.

Correspondence: Seyed-Babak Moosavi-Toomatari, MD, Students' Research Committee, Deputy for Research Affairs, Urmia University of Medical Sciences, Resalat Avenue, Djahad Square, Urmia, Iran, Telephone: +98(914) 1498-247, Fax: +98(441) 2231-930, E-mail: bmoosavit@gmail.com

Received for Publication: April 3, 2011, Accepted for Publication: June 25, 2011.

Abstract:

Introduction: Imaging methods are progressing in a rapidly manner, but the problem which we, as the health providers always encounter with is the expensive costs of different devices and our limited budget to provide them.

Aims: The aim of this study is to evaluate the usefulness of Histogram Equalization (HE) and Unsharp Mask (UM) on the conventional CXR images.

Methods and Material: In Urmia University of Medical Sciences, we designed a windows-based computer program that contains histogram equalization (HE), unsharp mask (UM) and combination of HE and UM algorithms with adjusted parameters to process conventional chest x-ray (CXR) images. Two series of CXR images including 49 images without major pulmonary disorder and 45 images with pulmonary parenchymal disorders were selected. After converting them to digital format, images were processed with HE, UM and combination of HE and UM techniques. In each series, original and processed images were saved in 4 databases. Two board-certified general radiologists (with 6 and 5 years experience) analyzed images. Saved images were displayed to radiologists randomly and separately. Quality of each image was saved as a scale from 1 (very low quality) to 5 (excellent). We used a variance-based statistical technique to analyze quality.

Statistical analysis used: To compare the quality of each algorithm (GHE, UM and combination of GHE and UM), a variance-based statistical analysis was done.

Results: In the first series images, HE and combination of HE and UM algorithms increased quality of images, but UM technique was not suitable, solely. Also, all three techniques increased quality of second series images.

Conclusions: The use of digital image processing algorithms such as HE or UM on conventional CXR images can increase quality of images.

Keywords: Image Processing, enhancement, Chest, Conventional, Radiography

Key Messages: The use of digital image processing algorithms such as HE or UM on conventional CXR images can increase quality of radiography images.

Introduction:

Imaging methods are progressing in a rapidly manner, but the problem which we, as the health providers always encounter with, is the expensive costs of different devices and our limited budget to provide them. Although recently, there are many new and useful methods for imaging, such as Magnetic Resonance Imaging (MRI), Positron Emission Tomography (PET scan) and etc, conventional radiographies are keeping their role in our diagnostic approach to the patients. Most of the time Radiography is the first step in imaging patients. This could be cost-saving, if we achieve diagnosis through conventional radiography.^(1, 2) Lots of radiographies are taken in radiology wards everyday that do not have suitable quality to interpret.⁽³⁾ This leads to incorrect diagnosis, unnecessary re-imaging, over exposure of personnel and patients and amortization of devices. These problems are more distinct in Intensive Care Unit (ICU) and Cardiac Care Unit (CCU), because of supine position and difficult positioning feature of patients and association with complications such as pleural effusion or ascites.⁽⁴⁾ There is no need to explain what can be occurred if we treat a patient with an incorrect diagnosis. X-ray is harmful for human and may lead to gene mutations and developing can-

cer. The most important factors to evaluate the severity of damage are total radiation dose, duration of exposure and exposure region.⁽⁵⁾

It is not easy for a health provider in a developing country to state "take a new one", when saw a device not to work in order. These issues make researchers to think about methods of image level enhancing. Image enhancement is one of the most important issues in low-level image processing.⁽⁶⁻¹⁰⁾ The commonly used techniques for contrast enhancement fall into two categories: (1) indirect methods and (2) direct methods. Indirect approaches mainly modify histogram by assigning new values to the original intensity levels. Histogram equalization is a popular indirect contrast enhancement method. However, histogram modification technique only stretches the global distribution of the intensity.⁽⁶⁾

In this study, we use global histogram equalization (GHE) and unsharp mask (UM) filters in processing conventional chest radiographies (CXR) to improve image quality and therefore, to decrease re-imaging, over-exposure and amortization of devices. In theory, histogram equalization makes optimal use of an available grey scale to display an image.⁽¹¹⁾ Global histogram equalization is a method to enhance the contrast of the whole image.⁽¹²⁾

Subjects and Methods:

The study was performed in 2008 after being approved by the Scientific and Ethical Review Board of Urmia University of Medical Sciences, Iran. We processed two series of radiographies with GHE, UM and combination of GHE and UM filters; a set of 49 radiographies of patients in ICU without major pulmonary disorder (first series) and a set of 45 radiographies of outpatients with major pulmonary disorders (second series). Original and processed images were displayed to board-certified radiologists (A.M., A.G.) separately and quality of each image was saved in a database.

Conventional radiographies were taken by a Philips device (Model D66 Made in Holland and USA, 1000 mA and 125 Kv) and printed on Orthochromatic AGFA films with a sensitivity of 400. To digitize conventional radiographies, we used a digital camera (Powershot a610 cannon). Images were taken with resolution 640*480 pixels in superfine Joint Photographic Experts Group (JPEG) format without flashing.

We designed a windows-based computer program with Delphi programming language. This software created four blank access databases for each series of radiographies that contain fields to save images, quality and code of images. Then each of original images were processed with GHE, UM and combination of GHE and UM techniques and saved with JPEG format in databases, randomly. As suggested before in the article of Pizer et al we need a single display to be used for both processed and unprocessed images.⁽¹³⁾ To display images to radiolo-

gists, we used a Pentium IV, 2.4GHz, Intel pc.

Two board-certified general radiologists (A.M. and A.G.) participated in this study. They had the following level of experience: reader 1, 6 years; reader 2: 5 years. Images of each database were displayed to each radiologist by 10-days intervals. Time of analysis was infinite. Quality of images interpreted by each reader was saved in the database on a scale from 1 as very low quality to 5 as excellent quality. None of the readers were aware about the interpretations of the other one, or also about which image is processed or un-processed (original).

To compare the quality of each algorithm (GHE, UM and combination of GHE and UM), a variance-based statistical analysis was done.

Results:

In the first series of radiographies, GHE and combination of GHE and UM algorithms had significant effect on quality improvement; but, there was no significant difference among them in improving. UM filter had no significant effect, solely. In second series of images, all three algorithms were suitable and enhanced quality of images (Table 1).

In first series of radiographies, all of three utilized methods (HE, UM, HE+UM) leads to increase in time needed to interpret image. But in second series, HE and combination of HE and UM lead to increase in required time. UM method did not make any increase in time needed to interpret images in the second series of images (Table 2).

Table1: Quality of Radiographies as interpreted by 2 different readers

		Original	HE	UM	HE+UM	P-value
1st Series	Dr A.M	2.22±0.51	2.65±0.6	2.27±0.64	2.63±0.64	<0.0001
	Dr A.G	1.61±0.86	3.35±0.88	1.94±0.88	3.84±0.83	0.0131
2nd Series	Dr A.M	2.67±0.64	3.82±0.53	2.73±0.65	3.6±0.84	<0.0001
	Dr A.G	2.71±0.69	3.44±0.92	2.89±0.83	3.58±1.03	<0.0001

HE: Histogram Equalization; UM: Unsharp Mask

Table2: Time required for interpretation of Radiographies (presented as seconds)

		Original	HE	UM	HE+UM	P-value
1st Series	Dr A.M	3.59±1.06	4.43±1.44	5.35±1.07	5.24±1.22	<0.0001
	Dr A.G	20.51±6.05	25.47±7.88	29.29±9.71	29.24±7.11	<0.0001
2nd Series	Dr A.M	8.13±1.56	3.87±1.75	7.64±2.25	4.16±0.88	<0.0001
	Dr A.G	20.71±4.14	15.07±2.87	19.56±4.02	15.11±3.11	<0.0001

HE: Histogram Equalization; UM: Unsharp Mask

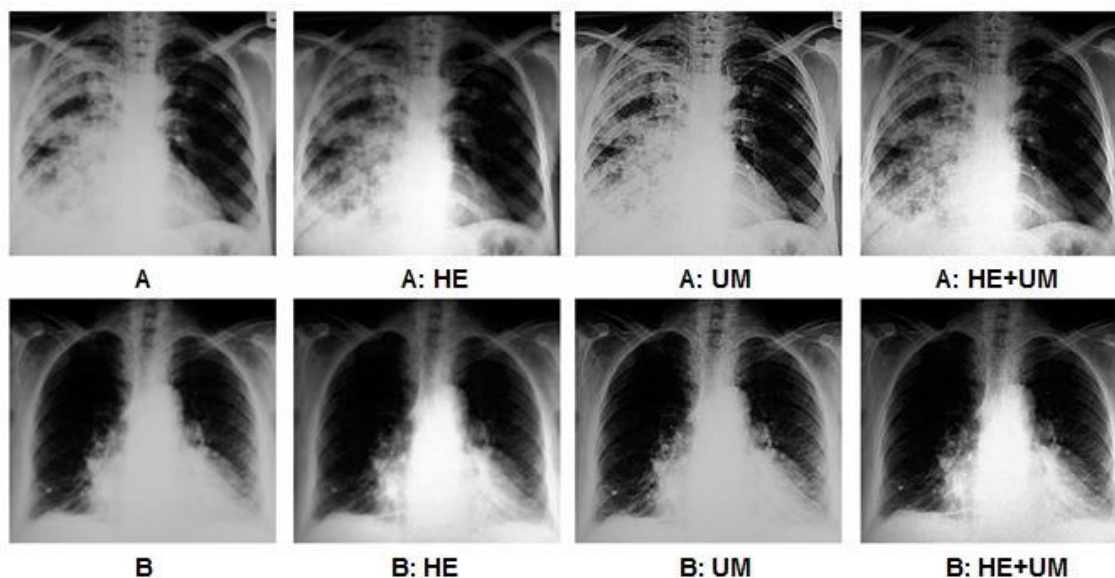
In the first series, these techniques make loculated pleural effusions more visible. This was possible by more visibility of the margins of loculated pleural effusions in portable radiographies (with low quality), lead to determination of liquid collection in pulmonary fissures. In these series of radiographies, it was not possible easily to evaluate post-cardiac area, but using these techniques, makes diaphragmatic and cardiac surface of lung more visible and therefore let us to precisely evaluate alveolar consolidations in the left-lower lobe (LLL) or collapsed lobes. This facilitates detecting pulmonary lesions among ICU admitted patients, which is our dilemma in patients with low levels of consciousness (without any respiratory symptoms). Detecting location of CVP catheters, tracheal or chest tubes were easier using both of these techniques, which were not possible in some samples because of inappropriate condition of radiography.

In the second series of radiographies with major pulmonary pathologies (results were compared with Computed Tomography Scan), all 2 techniques increase significantly the resolution of images (Figure 1). These techniques make interstitial nodules such as millitary TB pattern more visible by visualizing distances and boundaries between neighboring nodules and other structures. In radiographies with a basilar reticular pattern or linear consolidations in subpleural region such as Kerely B lines, theses findings were easier to diagnosis using image enhancement techniques. Comparing radiographies with CT- Scans or HRCTs demonstrated that these findings are not due to increased displayed image noise or artifacts, but related to real lesions in lungs. In patients with cavities of primary lung cancer, exactly evaluation of Air-Fluid levels and inner surface of lung cavity were possible by sharpening cavity mar-

gins after applying image enhancement techniques.

In the second series of radiographies, no significant difference was shown in evaluating alveolar lesions such as lobar pneumonia among original and processed

images. There was also a significant decrease in time needed to interpret in second series of radiographies, due to more possibility in evaluating lung lesions (Figure 1).



Picture 1, Applying HE and UM and HE+UM image processing methods in some samples of Chest X-ray. Two Images (A & B) with extensive pulmonary parenchymal disorders were evaluated with either of three image processing options (HE, UM, and HE+UM), then assessed and interpreted by two board-certified general radiologists.

Discussion:

Histogram equalization is a widely used image contrast enhancement method.⁽¹²⁾ Another algorithm we used in this study is Unsharp Masking, which allows significant data compression while improving the diagnostic quality of the image. Prokop believed that the most simple and still widely applied spatial filtering algorithms are based on unsharp masking,⁽¹⁴⁾ but we didn't yield favourable results in our study by using Unsharp Mask. Mentioned algorithms were used before in some studies to enhance different imaging methods such as MRI, mammography, scintigraphy, Radiation therapy, and etc. In all mentioned studies histogram equalization demonstrated favorable results.^(6, 14-19)

Pizer et al in their study declared that contrast enhancement such as histogram equalization, is often useful for optimal use for each image of the display intensity range.⁽¹³⁾ Though little evidences has been published before about the clinical usefulness of images processing and there remains considerable question as to whether processing increases lesion detectability to any significant extent, level enhancing has demonstrated undeniable results.⁽¹³⁾ Although our study proposed some doubts about the effectiveness of Unsharp Mask technique, but the findings generally advocated the application of level enhancement techniques. Some studies demonstrated increase in the visibility of anatomic structures, de-

spite increased displayed image noise and artifacts.^(11, 16, 20) Freedman in another study claimed that processing allows noise to be blurred so that it is less visible.⁽²¹⁾ Comparing radiographies with CT- Scans or HRCTs in our study demonstrated that the enhanced radiography findings such as basilar reticular patterns or linear consolidations are not due to increased displayed image noise or artifacts, but related to real lesions in lungs. Nowadays there is an obvious trend to what called "Tele Radiology". Tele Radiology is the approach to interpret radiographies by radiologist from distance, usually from home. By this system we could obtain second opinions from specialists. This could be very valuable especially in emergency cases, which you need more precise and scientific early interpretation. Tele-radiology is the main reason for using Digital Radiographs. This related mainly to its use as a data entry point method of projection radiography for high-quality teleradiology. Using digital camera to provide digital images from chest x-rays and using e-mails to send clinical data and attached images, provide us a low-cost tele-radiology system.^(22, 23)

Freedman discussed about the reason why digital images cannot be used currently by the radiologists to be interpreted. That is because radiologists are not familiar with the size of printed digital images, and there is a necessary period of learning for them to be adjusted with the new ones.⁽²⁴⁾ In our study we used a single monitor to display images to radiologists (readers), and no printed digital image was used. A limitation for our study is the use of digital camera in

order to provide digital images, however the study of Szot et al showed no significant difference in overall performance between reading from original x-ray films and digital images.⁽²³⁾

As mentioned in the results, time to interpret after processing original images were increased to some extent. This increasing needed time to interpret was justified as following; This technique improves the resolution successfully at the expense of increased reporting time, because more visualized anatomical structures and differentiating them from the pathological structures needs more time to assess and interpret.

References:

1. Kaneriya PP, Schweitzer ME, Spettell C, Cohen MJ, Karasick D: The cost-effectiveness of routine pelvic radiography in the evaluation of blunt trauma patients. *Skeletal Radiology* 1999, 28 (5): 271-273.
2. Santamaria F, Grillo G, Guidi G, Rotondo A, Raia V, de Ritis G, Sarnelli P, Caterino M, Greco L: Cystic fibrosis: when should high-resolution computed tomography of the chest be obtained? *Pediatrics* 1998, 101 (5): 908-913.
3. McNitt-Gray MF, Taira RK, Johnson SL, Razavi M: An automatic method for enhancing the display of different tissue densities in digital chest radiographs. *J Digit Imaging* 1993, 6 (2): 95-104.
4. Henschke CI, Yankelevitz DF, Wand A, Davis SD, Shiau M: Accuracy and efficacy of chest radiography in the intensive care unit. *Radiol Clin North Am* 1996, 34 (1): 21-31.
5. Takavar A: *Medical Physics*, 1st edn. Tehran: Noorpardazan Publishing Company; 1998.
6. Cheng HD, Shi XJ: A simple and effective histogram equalization approach to image enhancement. *Digital Signal Processing* 2004, 14 (2): 158-170.
7. Cohn M, Trefler M, Young TY: Enhancement and compression of digital chest radiographs. *J Thorac Imaging* 1990, 5 (1): 92-95.

8. Gonzalez RC, Wintz P: Digital Image Processing, 2nd edn: Addison-Wesley Publishing Company; 1987.
9. Joshi MA: Digital Image Processing: An Algorithmic Approach. New Delhi: Prentice Hall of India; 2006.
10. Umbaugh SE: Computer Vision and Image Processing: . New York: Prentice Hall; 1999.
11. Lehr JL, Capek P: Histogram equalization of CT images. Radiology 1985, 154 (1): 163-169.
12. Zhu H, Chan FHY, Lam FK: Image Contrast Enhancement by Constrained Local Histogram Equalization. Computer Vision and Image Understanding 1999, 73 (2): 281-290.
13. Pizer SM, Todd-Pokropek AE: Improvement of scintigrams by computer processing. Seminars in Nuclear Medicine 1978, 8 (2): 125-146.
14. Prokop M, Neitzel U, Schaefer-Prokop C: Principles of image processing in digital chest radiography. J Thorac Imaging 2003, 18 (3): 148-164.
15. Braunstein EM, Capek P, Buckwalter K, Bland P, Meyer CR: Adaptive histogram equalization in digital radiography of destructive skeletal lesions. Radiology 1988, 166 (3): 883-885.
16. Fujita M, Kodera Y, Ogawa M, Tanimoto K, Sunayashiki T, Wada T, Doi K: Digital image processing of dentomaxillofacial radiographs. Oral Surg Oral Med Oral Pathol 1987, 64 (4): 485-493.
17. Redlich U, Hoeschen C, Doehring W: Assessment and optimisation of the image quality of chest-radiography systems. Radiat Prot Dosimetry 2005, 114 (1-3): 264-268.
18. Rehm K, Seeley GW, Dallas WJ, Ovitt TW, Seeger JF: Design and testing of artifact-suppressed adaptive histogram equalization: a contrast-enhancement technique for display of digital chest radiographs. J Thorac Imaging 1990, 5 (1): 85-91.
19. Solowsky EL, Reinstein LE, Meek AG: An assessment of a film enhancement system for use in a radiation therapy department. Med Dosim 1990, 15 (3): 107-112.
20. Zimmerman JB, Cousins SB, Hartzell KM, Frisse ME, Kahn MG: A psychophysical comparison of two methods for adaptive histogram equalization. J Digit Imaging 1989, 2 (2): 82-91.
21. Freedman MT, Artz DS: Image processing in digital radiography. Semin Roentgenol 1997, 32 (1): 25-37.
22. Lissner J, Fink U: Digital imaging and picture archiving and communication systems. Curr Opin Radiol 1991, 3 (2): 267-274.
23. Szot A, Jacobson FL, Munn S, Jazayeri D, Nardell E, Harrison D, Drosten R, Ohno-Machado L, Smeaton LM, Fraser HS: Diagnostic accuracy of chest X-rays acquired using a digital camera for low-cost telerradiology. Int J Med Inform 2004, 73 (1): 65-73.
24. Freedman MT, Artz DS: Digital radiography of the chest. Semin Roentgenol 1997, 32 (1): 38-44.